High density mapping in atrial fibrillation

Jin-Bae Kim, MD, PhD.
Cardiology Division, CardioVascular Center
Kyung Hee Univ College of Medicine, Seoul, Korea

Disclosure

- none

Difference of Resolution

Emergence of Multielectrode Mapping

On the Road to Higher Resolution

- In 1999, single-point catheter-based mapping was first validated using the CARTO system with 75 endocardial points.
- Seventeen years later, the validation of an automated mapping system (Rhythmia; Boston Scientific) with microelectrodes on a miniature basket catheter was demonstrated with an average of >8000 mapping points.

Problem in mapping

- Spatial averaging
- Ringing artifact

Roderick Tung

- Smaller electrode catheters increase the sensitivity to identify normal surviving bundles of myocardium, relative to large tipped catheters.

- A smaller interpolattion distance requires a greater number of points to be mapped, but provides more accurate mapping.

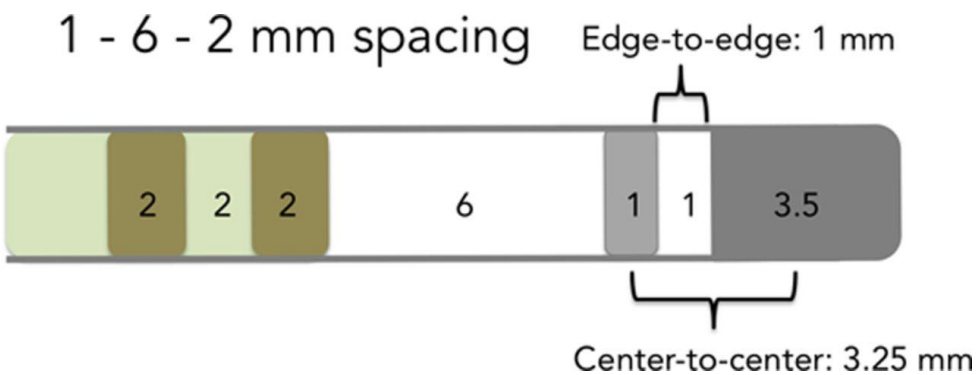

Electrode size and spacing on a ThermoCool SF Ablation Catheter.

Catheter profiles

Table. Summary of Various Electrode Configurations, Sizes, and Relative Spacing With Commonly Used Catheters

Model	Manufacturer	Electrodes	Tip Electrode Size, mm	Ring Electrode Size, mm	Spacing (Edge-to-Edge)	Spacing Recorded (Center-to-Center)
Ablation catheters						
ThermoCool ST	Biosense Webster	4	3.5	1	1-6-2	3.25
ThermoCool SF	Biosense Webster	4	3.5	1	2-5-2	4.25
Navistar	Biosense Webster	4	4/8	1	1-7-4	3.50
CoolFlex	St. Jude Medical	4	4	1	0.5-5-2	2.75
Safire/Cool Path	St. Jude Medical	4	4	2	2-5-2	5.00
FlexAbility	St. Jude Medical	4	4	1	1-4-1	3.50
Tacticath	St. Jude Medical	4	3.5	1	2-5-2	4.25
Blazer II/OI	Boston Scientific	4	4	2	2.5-2.5-2.5	4.50
MiFi	Boston Scientific	4	…	1	1.5 mm	2.50
Multielectrode mapping						
PentaRay	Biosense Webster	20	…	1	2-6-2	3.00
Decapolar	Biosense Webster	10	2.4	1	2-8-2	3.00
Lasso	Biosense Webster	20	…	1	2-6-2	3.00
Duodecapolar (Livewire)	St. Jude Medical	20	2	1	2-2-2	3.00
IntellaMap Orion	Boston Scientific	64	…	0.9×0.45	1.6 mm	2.50
Constellation (60 mm)	Boston Scientific	64	…	1.5 mm	5	6.50
Inquiry Optima	St. Jude Medical	24	…	1	1-4.5-1	…
Inquiry AFocus II	St. Jude Medical	20	…	1	4	…

High Resolution Mapping

INTELLAMAP ORION™ HIGH-RESOLUTION MAPPING CATHETER

The IntellaMap Orion is a 64-electrode catheter designed to safely measure signals from all cardiac chambers.

- ✓ 8.5F, bi-directional steerability
- ✓ 64-electrodes, 8 splines
- ✓ Variable deployment, 3-22mm diameter
- ✓ Deployment control located on handle – no long sheath required
- ✓ Connects to the Signal Station with a single connector





High-density chamber coverage provides contact electrograms less than 2mm from any point on the map.[1]

High Resolution Mapping

Annotation criteria

- ✓ Two reference electrograms (EGM; one main [R] and one additional [ΔR]) were chosen on the decapolar catheter.
- ✓ Cardiac beats were automatically selected for inclusion in the map based on cycle length (CL) stability, stable relative timing of 2 reference EGM, electrode location stability, and respiratory gating.
- ✓ The window of interest is automatically set by the system at the CL value and centered on the main reference EGM.
- ✓ For annotation of the local activation time of each acquired bipolar EGM, the system combines unipolar (maximum negative dV/dt) and bipolar (maximum amplitude) EGM.

Fractionation in HD mapping

- ✓ EGM fractionation over areas of interest was defined as ≥4 deflections, lasting more than 40msec

1)Slow conduction (SC);

2) lines of block (LB)

3) pivot site (PS)

4) wavefront collision (WFC) and

5) gap

Slow conduction

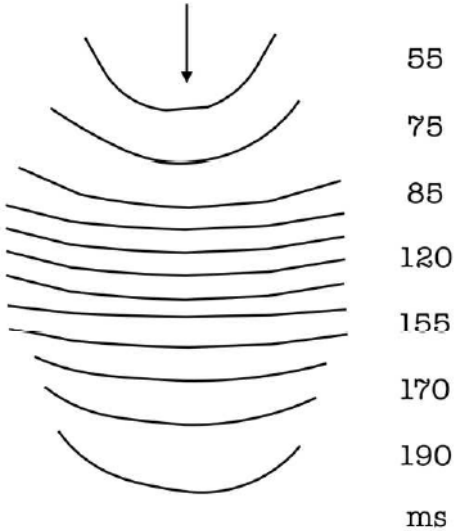

Wave front collision

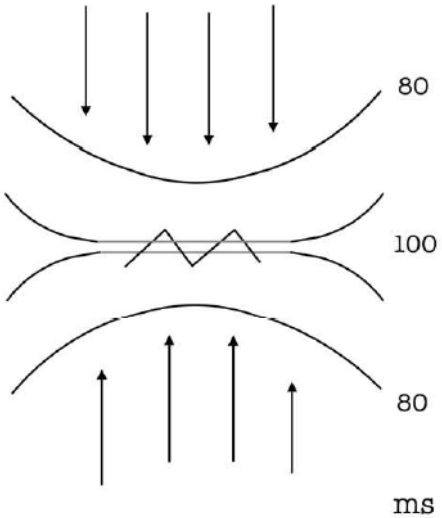

Pivot site (ms)

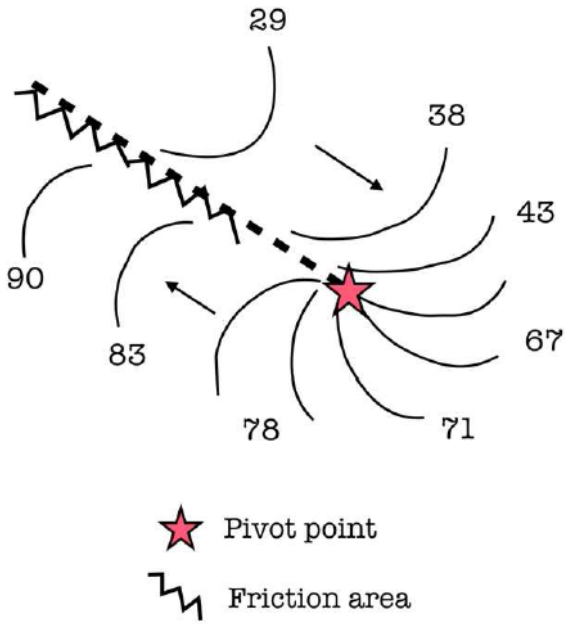

Line of Block

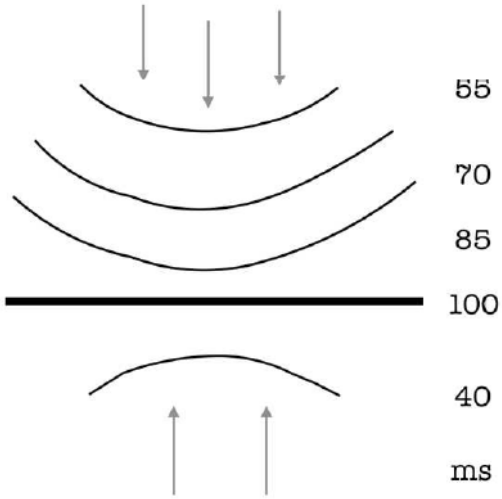

Gaps

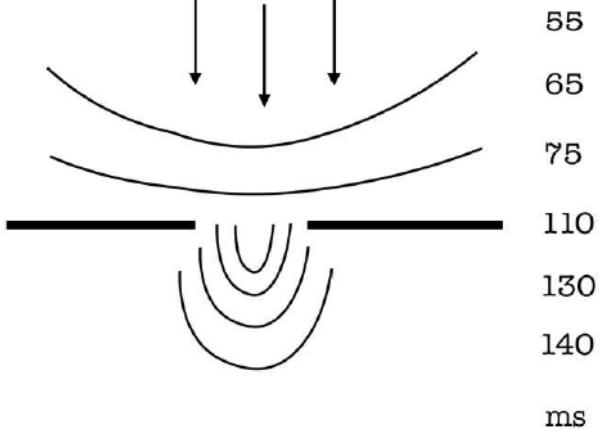

HD mapping in AF

1. Finding gap and confirming PV isolation.
2. Mapping the AT after PV isolation and define the exact mechanism of AT, eg, focal Vs microreentrant.
3. Confirming the line of block, showing the small channel in the ablation line or epicardial breakthrough.

Gap detection and PVI

Identification of pulmonary vein reconnection gaps with high-density mapping in redo atrial fibrillation ablation procedures

Ignacio García-Bolao[1*†], Gabriel Ballesteros[1†], Pablo Ramos[1], Diego Menéndez[1], Ane Erkiaga[2], Renzo Neglia[1], Marta Jiménez Martín[1], and Enrique Vives-Rodríguez[1]

[1]Department of Cardiology and Cardiovascular Surgery, Clínica Universidad de Navarra, Avenida Pío XII, 36 (31008) Pamplona, Spain; and [2]Boston Scientific Corporation

- Comparing HD mapping and conventional 3D mapping with circular catheter

Europace 2018

Gap detection and PVI

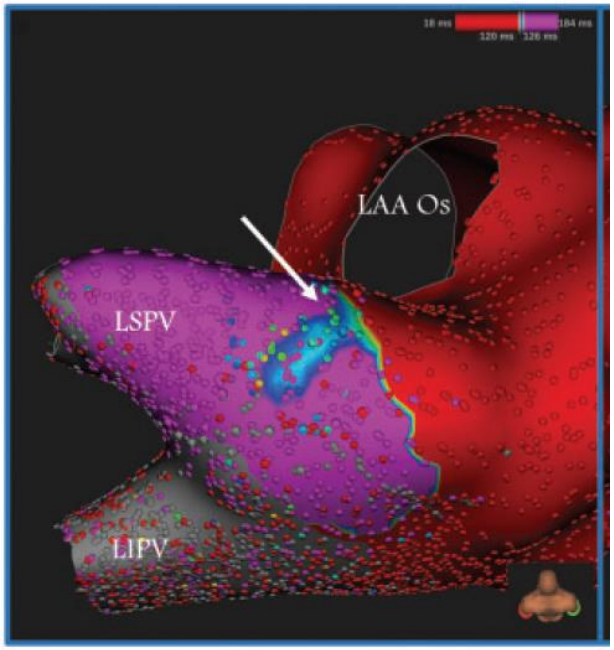

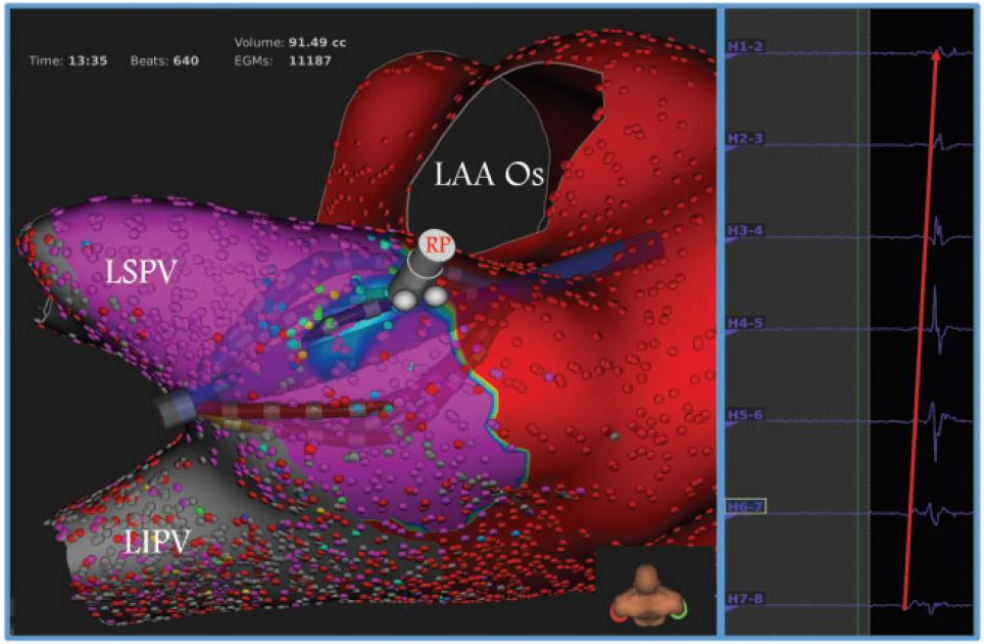

Europace 2018

Gap detection and PVI

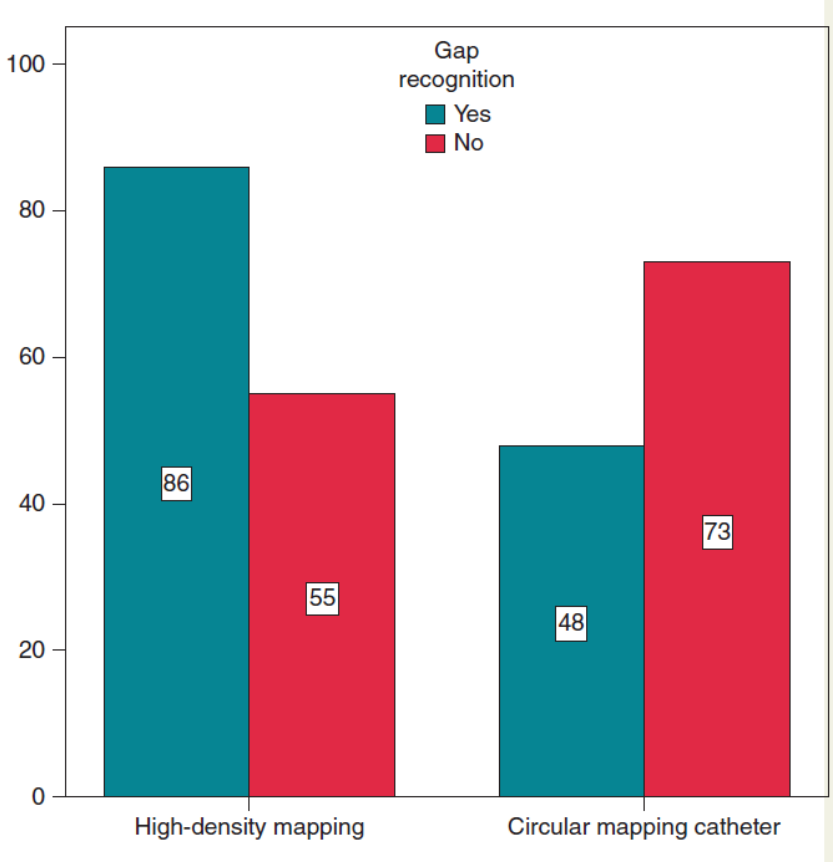

Successful recognition of the reconnection gap

The HDM group (86 of 141; 60.99%) the control group (48 of 121; 39.66%; P=0.001).

Europace 2018

Micro-reentrant tachycardia

Micro-reentrant tachycardia: circuit size < 2 cm

Saoudi N, et al. Journal of Card Electrophy 2003

Localized Atrial Reentrant Tachycardia in Tetralogy of Fallot

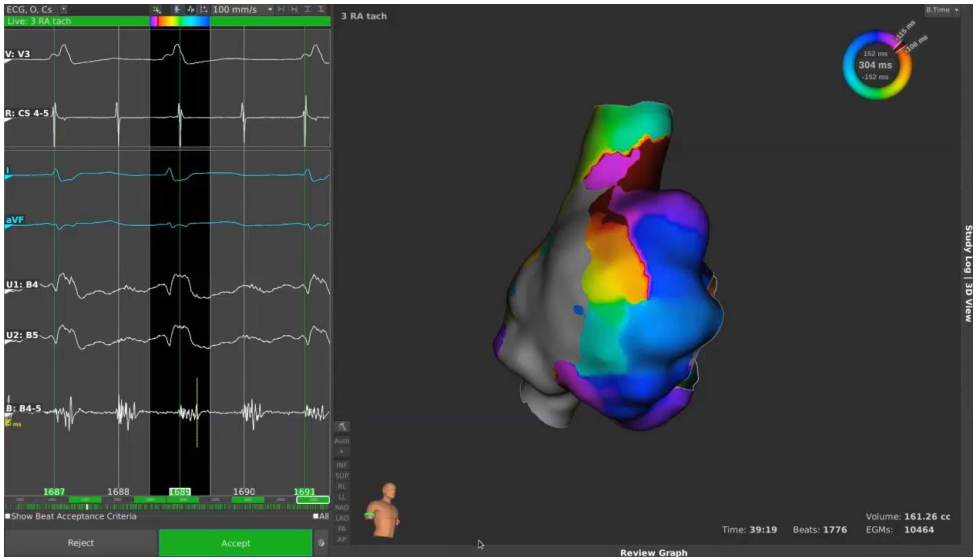

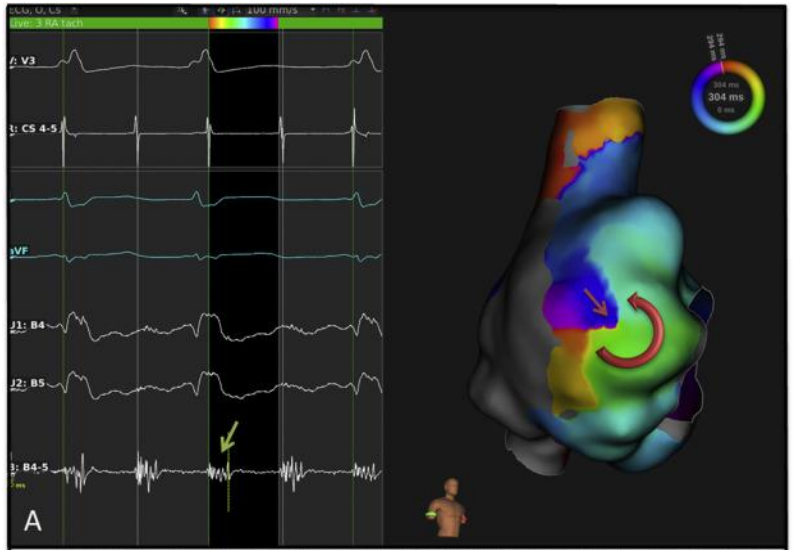

Adam Lee, et al. Heart Rhythm 2017

Micro-reentrant tachycardia

Characterizing localized reentry with high-resolution mapping: Evidence for multiple slow conducting isthmuses within the circuit

Check for updates

Antonio Frontera, MD,*† Rajiv Mahajan, MD, PhD,‡ Corentin Dallet, PhD,† Konstantinos Vlachos, MD,* Takeshi Kitamura, MD,* Masateru Takigawa, MD, PhD,* Ghassen Cheniti, MD,* Claire Martin, MD,* Josselin Duchateau, MD,* Anna Lam, MD,* Felix Bourier, MD,* Arnaud Denis, MD,* Thomas Pambrun, MD,* Meleze Hocini, MD,* Frederic Sacher, MD, PhD,* Nicolas Derval, MD,* Michel Haïssaguerre, MD,*† Remi Dubois, MD, PhD,† Pierre Jaïs, MD*†

*From the *Hôpital Haut Leveque, Pessac, France, †LIRYC Institute, Pessac, France, and ‡Lyell McEwin and Royal Adelaide Hospitals, South Australian Health and Medical Research Institute and University of Adelaide, Adelaide, Australia.*

Heart rhythm 2019

Micro-reentrant tachycardia

Two forms of localized reentrant circuits.

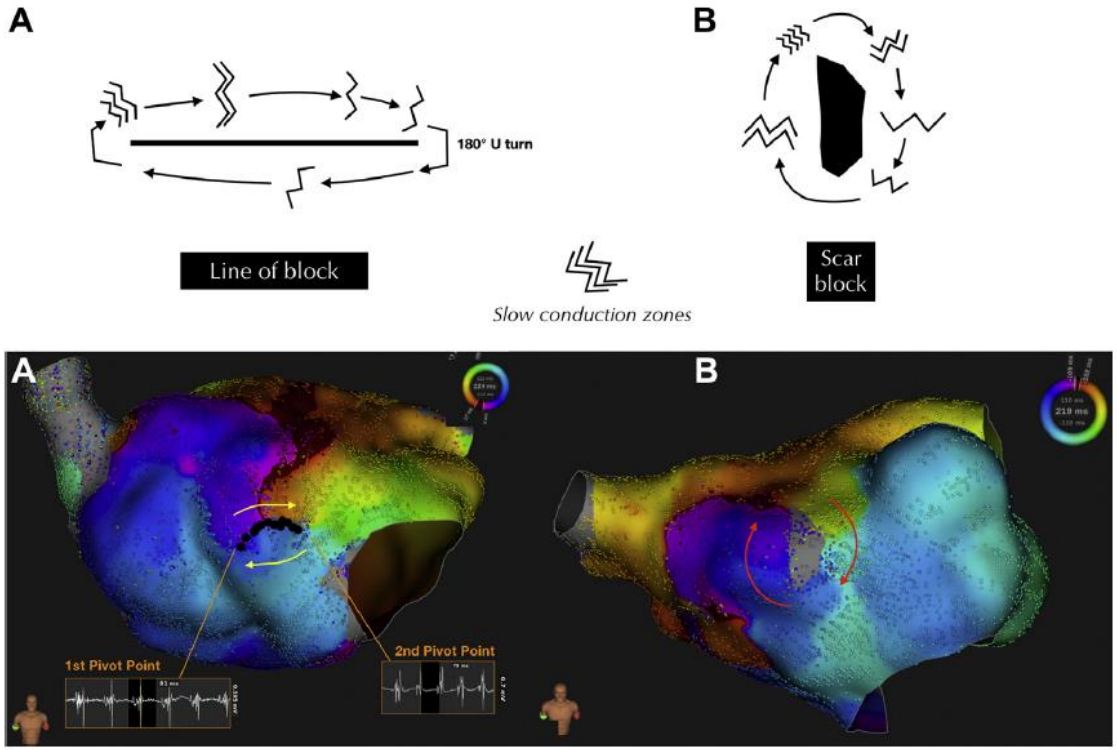

A: Lines of block delimitate the circuit.
B: A central area of scar around which the localized reentrant circuit turns around.

Heart rhythm 2019

Line of block

ORIGINAL ARTICLE

Pseudoblock of the Posterior Mitral Line With Epicardial Bridging Connections Is a Frequent Cause of Complex Perimitral Tachycardias

Circ AE 2019

Line of block

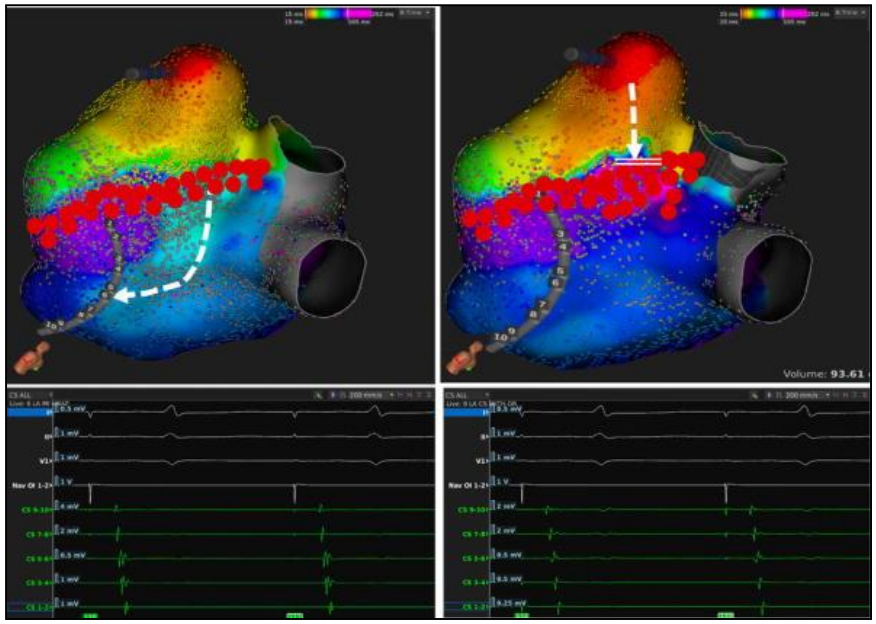

Pseudoblock across a posterior mitral line with residual endocardial conduction.

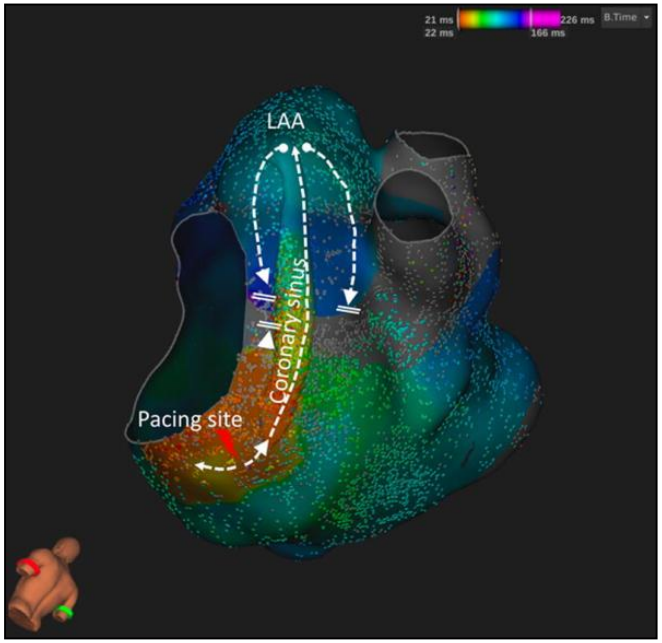

Anatomic distribution of the bridging endocardial-epicardial connections.

Circ AE 2019

(A) Confidence mask: 0.04mV

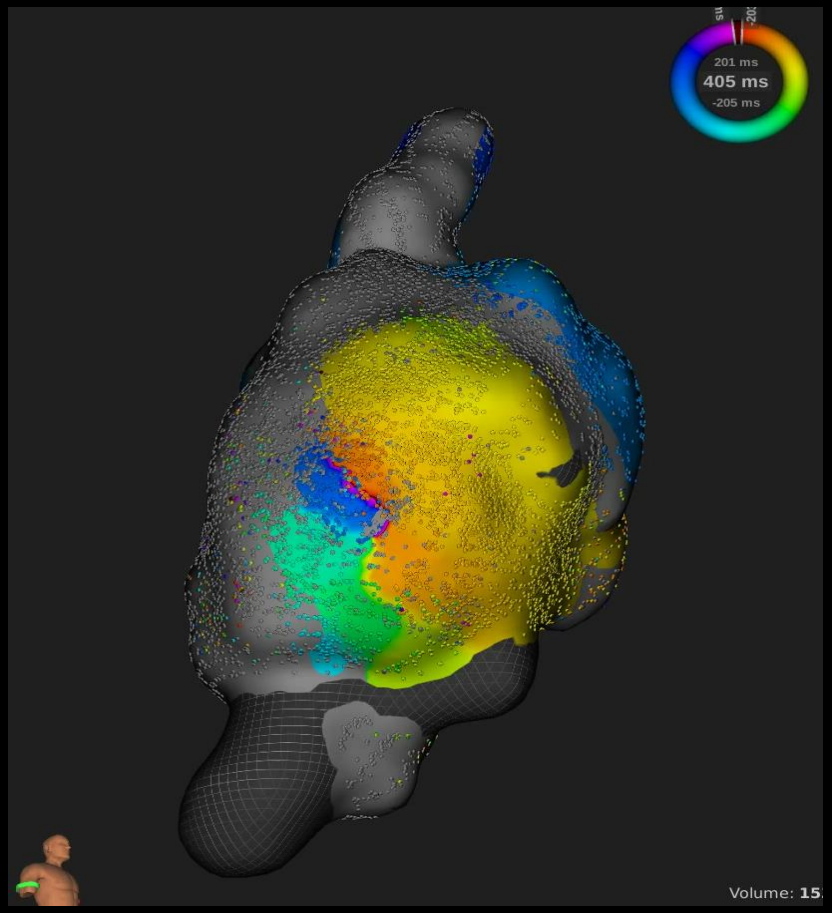

(B) Confidence mask: 0.2mV

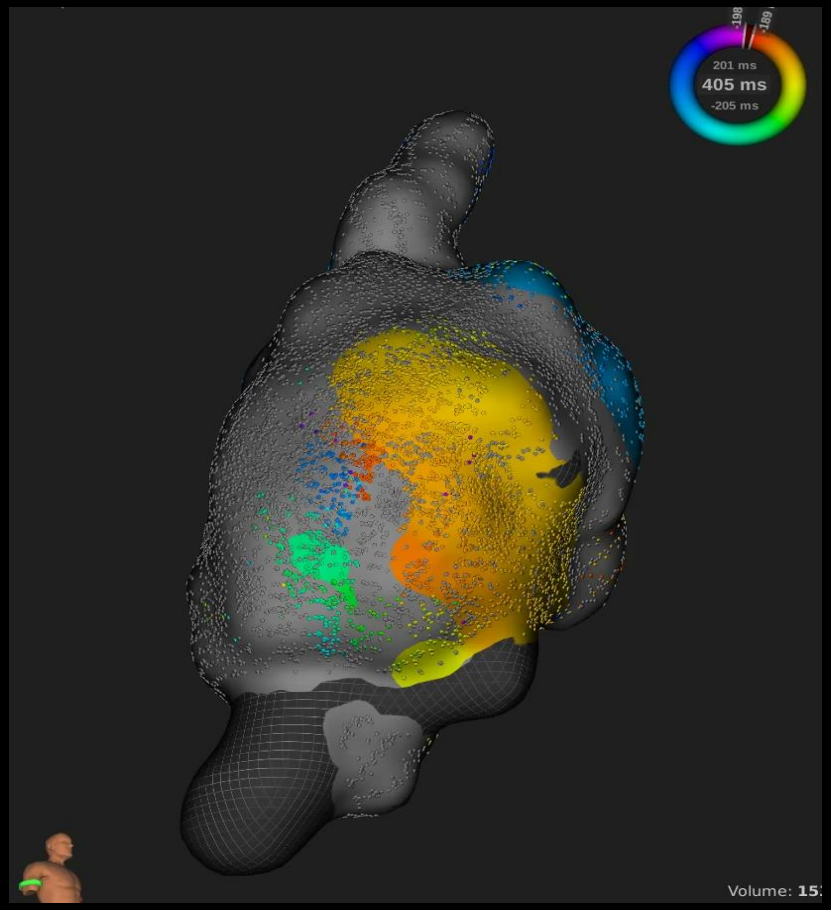

Heart Rhythm 2019

Limitation of HD mapping

- Noise problem
- Setting of WOI
- Relative prolonged mapping
- EP knowledge and experience

Limitation of HD mapping

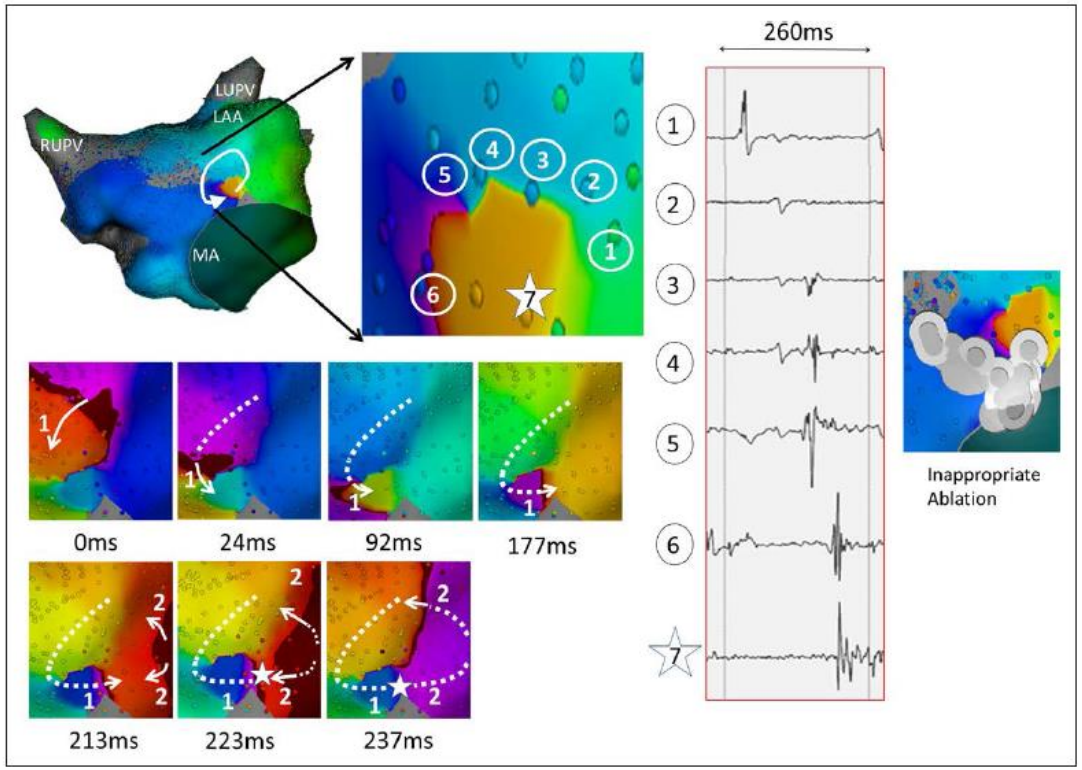

A secondary wavefront (labeled 2) travelling toward this area of low voltage collided with the head of the primary wavefront (starred—site 7) and advanced activation around (site 1–2) creating the impression of reentry.

Circulation AE 2017

Limitation of HD mapping

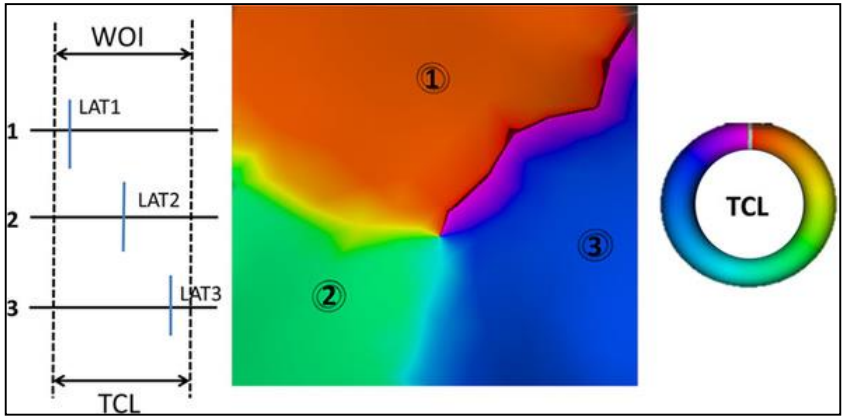

Carousel activation can be seen from just 3 closely spaced points with different annotation of local activation timing across the window of interest

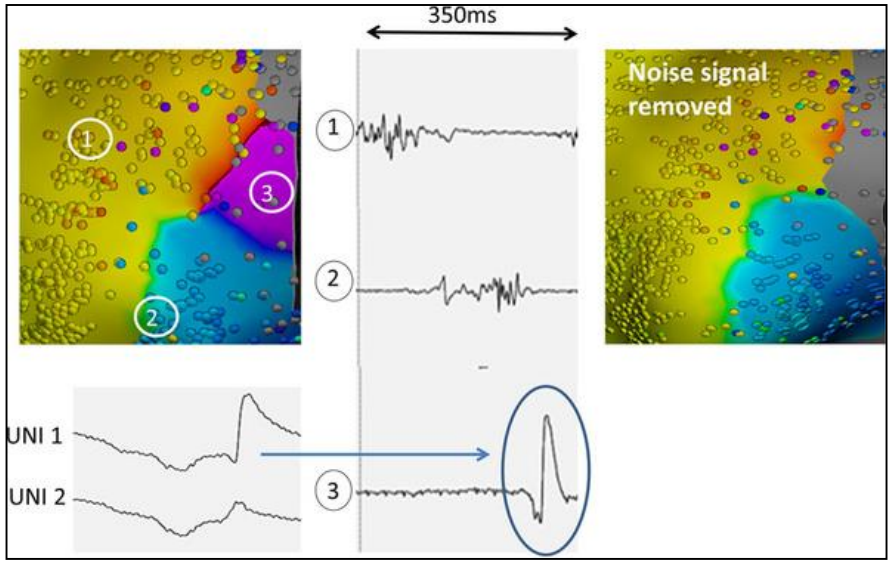

Carousel was seen within an area of low-voltage signal rotating around a pinwheel. removing the noise signal, carousel activation was no longer evident

Circulation AE 2017

Conclusion

- Ultra–high electro-anatomic density mapping (10 000 points per map) improved electrogram resolution for activation mapping.
- This has enabled a better understanding of different tachycardia mechanism, especially within lowvoltage myocardium.
- However, the effects of HD mapping would largely depend on physician's knowledge and experience.